

# Understanding Digital Dermatitis




By: Alexis Thompson and Jeffrey Bewley, Ph.D.


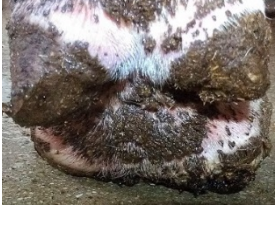
Digital dermatitis is an infection caused by bacteria which produces a painful wart on the heel inducing lameness (Hoffman, 2012). Digital dermatitis, also known as hairy heel warts, strawberry foot, digital warts, Mortellaro or interdigital papillomatosis, is a growing concern for the dairy industry. As an infectious disease, digital dermatitis threatens the biosecurity and welfare of a farm. Dairy producers should focus on identification and treatment of cases, and management for control of spread and prevention of the condition.

## Identifying Digital Dermatitis

The bacterium which leads to digital dermatitis is thought to be associated with the spirochete *Treponema* spp, although some debate does exist. This bacterium is believed to infect deep within the dermal layer of the feet. When active, it produces a wart-like growth described as being 0.75 to 2.5 inches in diameter (larger than the size of a penny), circular or oval shaped, and raised (Döpfer et al., 1997, Read and Walker, 1998). Sometimes the skin around the growth is red with irritation, but this is not always the case.

Most often, the warts are classified in 5 categories: not present, small growth, large growth, healing, and chronic. In the case of large or chronic growths, the bacteria imbed themselves in the dermal layer and continuously produce growths. These cows will permanently encounter digital dermatitis (Döpfer et al., 1997). With control, the bacteria may become dormant in the heel but will become active if irritated. Early detection increases the possibility a successful treatment (Shearer and Hernandez, 2000).

Category	Description	Picture(s)
Not Present	Normal digital skin without signs of Digital Dermatitis. The skin is flesh colored with normal hair.	
Small Growth	Early, small circumscribed red to gray epithelial defect of less than 0.75 inches (less than the size of a penny) in diameter. Skin can have slight pink discoloration. The growth does not affect gait.	
Large Growth	Acute, active ulcerative (bright red) or granulomatous (red-gray) digital skin alteration. Greater than 0.75 inches in diameter. Large, coarse hairs may sprout from the wart surface. Surrounding skin may be inflamed. The growth is extremely painful and the cow will kick when the wart is palpated. The cow may toe when she walks.	

<p>Healing</p>	<p>Healing stage within 1 to 2 days after topical therapy, where the acute DD lesion has covered itself with a firm scab-like material. The growth will become smaller. A light pink circle may develop around the growth as scarring occurs. The cow may toe when she walks though this stage does not generally affect gait.</p>	
<p>Chronic</p>	<p>Late chronic lesions that may be dyskeratotic (mostly hard and thickened epithelium), proliferative (numerous or continuous warts), or both. The proliferations may be filamentous (contain coarse hairs), scab-like, or mass proliferations. The cow can either have chronic lameness or no distortions in gait.</p>	

**Table 1: Classification of digital dermatitis using the procedure described by Döpfer of University of Wisconsin-Madison (Döpfer et al., 1997)**

**Prevention of Initial Infection**

The cows most susceptible to digital dermatitis are transition cows. These cows are experiencing stress from calving and pen movements, which lowers their ability to fight infection. During the dry period, cows often lack a preventive footbath regimen (Cook et al., 2004). Digital dermatitis bacteria may be present on the limbs of the cow in a dormant stage.

The goal to preventing lameness caused by digital dermatitis is to avoid infecting first calf heifers (Cook et al., 2004). Limiting contact between first lactation cows and infected cows reduces the chance of transmission. The severity and frequency of digital dermatitis increases the more often a cow is exposed to bacteria. If a cow is exposed at a young age, she is more likely to develop larger or chronic growths and becomes a risk to other cows in the herd.

Digital dermatitis is a biosecurity risk; farms that bring in cows from other farms tend to experience a higher prevalence of the disease. Cows coming from external sources should be quarantined with limited access to the general herd for a month. During this time, these cows should use a footbath to eliminate any digital dermatitis bacteria and should have their feet checked carefully for growths.

**Digital Dermatitis and Lameness**

In recent years, the percentage of lameness cases caused by digital dermatitis has grown at an alarming rate. Lameness is a symptom of digital dermatitis, but may not develop. Cows that develop lameness tend to have more severe warts and walk on their toe when they are walking which wears their toes. Lameness results in decreased feed intake, lower milk production, and poor reproductive performance. These factors increase the risk of culling. A case of lameness costs an average of \$133 (Cha et al., 2010). Reproductive decline and milk losses are a significant proportion of the cost. Control and prevention of digital dermatitis is crucial as it accounts for over half of all lameness cases (Highlights of NAHMS Dairy 2002: Part III, Vet. Serv., 2003).

Early detection and treatment of digital dermatitis minimizes losses, improves outcomes, and reduces animal suffering (Shearer and Hernandez, 2000). Milking is an optimal time to visually detect digital dermatitis because early growths do not always present with lameness. Performing feet checks as the cows stand to be milked by merely walking along the pit looking at the backs of the feet with a flashlight for indications of dermatitis (presence of warts, matted hair) can help determine the prevalence and severity of digital dermatitis in a herd.

Farmers should aim for most of their herd to be in the not present or small growth stages of the warts. Cows with large growths actively spread the bacteria, which infect other cows. Chronic cows and

**Educational programs of Kentucky Cooperative Extension serve all people regardless of race, color, age, sex, religion, disability, or national origin.**

## Understanding Digital Dermatitis

cows with large growths become a risk to young stock and uninfected lactating cows. Prevention is vital because lameness causes pain and discomfort, resulting in poor performance.



Figure 1. A cow exhibiting the pain avoidance stance often associated with digital dermatitis.